

Alveolar bone grafting: a review of 115 patients

M. Collins*, D. R. James** and M. Mars**

*UMDS of Guy's and St Thomas's Hospitals and **The Hospital for Sick Children, Great Ormond Street, London, UK

SUMMARY The results of alveolar bone grafting carried out at The Hospital for Sick Children, Great Ormond Street, London, UK, between January 1982 and January 1989 were assessed. Cancellous bone from the iliac crest was grafted to alveolar cleft defects in 115 patients (63 male and 52 female). Eighty-seven unilateral (58 left and 29 right) and 28 bilateral clefts were operated on. The mean age at the time of operation was 11.5 years, with a range of 8.08–18.75 years. The cleft canine had erupted prior to bone grafting in 58.4 per cent. At the time of this study the cleft had erupted in 96.35 per cent and was unerupted in 3.65 per cent of sites. Radiographs were taken at regular intervals and assessed according to previously reported criteria. Eighty-six per cent were clinically successful (Type I and II). In Type III 10.95 per cent had less than three-quarters of the normal interdental septal height and 2.18 per cent failed (Type IV). In addition, 3.6 per cent of sites showed cervical root resorption affecting the adjacent incisor and 1.4 per cent internal resorption of the cleft canine.

Introduction

The main objectives of secondary bone grafting are: to fill the residual osseous cleft of the alveolus and anterior palate (Boyne and Sands, 1972); to give support to the alar base (Carlton Schultz, 1989; Jackson *et al.*, 1982); to eliminate oro-nasal fistula (Boyne and Sands, 1976; Eldeeb *et al.*, 1986) and mucosal recesses (Bergland *et al.*, 1986); to enhance maxillary stability, especially in bilateral clefts with mobile premaxillae (Åbyholm *et al.*, 1981) and to consolidate the maxilla to facilitate secondary surgery (Amanat and Langdon, 1991); to obtain functional bony tissue in the donor site into which teeth, in particular the upper canine, could erupt spontaneously and, hence, to facilitate the achievement of a non-prosthetic result (Bergland *et al.*, 1986); to give bony support to the adjacent dentition (Kortebein *et al.*, 1991); to facilitate final prosthetic restoration by improving vestibular soft-tissue relations (Åbyholm *et al.*, 1981), alveolar height and contour (Kortebein *et al.*, 1991); to provide bone for subsequent placement of osseointegrated implants (Verdi *et al.*, 1991) and autologous transplants (Hillerup

et al., 1987) and to improve dental and facial aesthetics.

There remain few advocates of primary bone grafting (Rosenstein *et al.*, 1991). Secondary bone grafts are more popular and can be placed at three stages: at 2–5 years, at the optimal time of 6–15 years or late secondary bone grafting after this time (Boyne and Sands, 1972). As sagittal and transverse growth has virtually ceased by 8–9 years (Bergland *et al.*, 1986), the chances of interfering with maxillary growth are minimal after this age. However, vertical growth continues until adolescence and is affected by secondary bone grafting (Enemark *et al.*, 1987). Extensive mobility of the palatal mucosa during surgery may result in reduced vertical development of the maxilla (Enemark *et al.*, 1985, 1987).

Cancellous bone grafts are favoured over cortical bone due to the abundance of osteogenic surface cells, many of which survive and initiate new bone formation (Åbyholm *et al.*, 1981). Allogenic bone (Maxson *et al.*, 1990) and hydroxylapatite (Eppley *et al.*, 1986) have also been grafted. The iliac crest is the most popular site for obtaining the graft material because of its abundance of cancellous bone which transforms rapidly into alveolar bone (Bergland *et al.*, 1986).

*Now at The Royal London Hospital

Cancellous bone has also been procured from the calvarium (Sandove *et al.*, 1990), the mandible (Sindet-Pedersen and Enemark, 1988) and the tibia (Lilja *et al.*, 1987).

Subjects and methods

This study was undertaken to assess the outcome of bone grafts performed at Great Ormond Street between January 1982 and January 1989. During this time, 115 patients, 63 male and 52 female, were operated on. The racial distribution included 106 Caucasians, seven Asians, one Afro-Caribbean, and one Oriental. Eighty-seven patients had unilateral (58 left and 29 right) and 28 bilateral clefts. The total number of cleft sites was thus 143. The mean age at the time of operation was 11.59 years, with a range of 8.08–18.75 years.

In accordance with the guidelines laid down by Åbyholm *et al.* (1981), orthodontic expansion was carried out in the majority of cases prior to grafting cancellous bone from the iliac crest into the alveolar cleft. Anterior occlusal radiographs (through the midline and the cleft) were routinely taken pre- and post-operatively. Post-operative radiographs were taken at 6 weeks, and then at 3, 6, 9, and 12 months. Additional radiographs were taken at infrequent intervals.

The results of this study were based on the anterior occlusal radiographs in 67 patients (58 per cent), anterior occlusals and periapicals in 42 patients (36 per cent) and an orthopantomogram in one patient (0.8 per cent). The radiographs were missing in five patients (4.3 per cent). The assessment was carried out at a mean of 4.5 years post-surgery with a range of 1–9 years. The height of the interalveolar septum was recorded according to the criteria of Bergland *et al.* (1986):

- Type I septum height approximately normal.
- Type II septum height at least three-quarters of normal.
- Type III septum height less than three-quarters of normal.
- Type IV absence of a continuous bony bridge across the cleft.

The position of the cleft canine was also recorded both pre- and post-bone grafting.

Results

As radiographs were missing in five patients, one of whom had a bilateral cleft, the results are based on 137 cleft sites.

The eruption of the cleft canine

The upper canine was unerupted in 58.4 per cent (80) and erupted in 41.5 per cent (57) of sites prior to bone grafting. Post-bone grafting, the upper canine had erupted in 96.35 per cent (132) and remained unerupted in 3.65 per cent (five) of clefts.

The interalveolar septal height

The results were as follows:

- Type I 45.99 per cent (63) of clefts.
- Type II 40.88 per cent (56) of clefts.
- Type III 10.95 per cent (15) of clefts.
- Type IV 2.18 per cent (3) of clefts.

Type I and II are clinically acceptable. Thus, 86.86 per cent of bone grafts were successful. The Type III group was composed of 11 patients including six male, five female, nine Caucasians, and two Asians. Of the clefts, five were unilateral (four left and one right) and six bilateral (involving both sides in four cases, and one side in two cases). The cleft canine was unerupted in five sites and had erupted in 10 sites prior to surgery. The cleft canine had erupted post-operatively in all cases. The mean age at the time of operation was 11.7 years and the mean time of assessment was 5.8 years post-surgery. Two clefts were operated on in 1983, six in 1984, three in 1985, two in 1986, and two in 1987. The Type IV group comprised three Caucasians, two male, and one female. The clefts were unilateral and on the left side. The cleft canine was unerupted in two cases and erupted in one case prior to bone grafting. The canine had erupted in all cases post-surgery. The mean age at the time of the operation was 12.6 years. Two of the operations were performed in 1983 and one in 1986.

Dental resorption

Five (3.6 per cent) sites showed cervical resorption affecting the adjacent incisor and 2 (1.4 per cent) showed internal resorption of the cleft canine.

Discussion

Bone height

Figure 1 shows an anterior occlusal radiograph taken through the cleft site. It highlights the absence of bone prior to bone grafting. Figure 2 is a post-bone grafting anterior occlusal radiograph of the same patient showing a successful bone graft with the erupted cleft canine. This case is illustrated clinically in Figures 3, 4, and 5. Figure 3 is an occlusal view of the cleft palate and Figure 4 a view of the buccal occlusion on the cleft side prior to treatment. Figure 5 shows the buccal occlusion on the cleft side after bone grafting and orthodontic treatment. The interalveolar septal height was used to assess the success of the bone graft. Although the results were evaluated between 1–9 years post-surgery, the bone height level appeared to be stable after 6 months, with a clinical success rate of 86.86 per cent. This compares favourably with the 90 per cent success rate of Bergland *et al.* (1986), the 83 per cent success rate of Amanat and Langdon (1991) and the 80 per cent success rate of Jackson *et al.* (1982). However 10.9 per cent were Type III and 2.1 per cent failed. Attempts were made to evaluate the reasons for failure.

Unilateral versus bilateral. Nine per cent of unilateral clefts were Type III or IV compared with 21.4 per cent of bilateral clefts. Hall and Posnick (1983) also found less favourable results in bilateral clefts and Åbyholm *et al.* (1981) attributed this to poor immobilization of the pre-maxilla in the post-operative phase.

The stage of development of the canine. Of the canines which had erupted prior to surgery, 19.3 per cent ended up with a Type III or IV bone graft. By contrast only 8.7 per cent of canines which were unerupted prior to surgery ended up

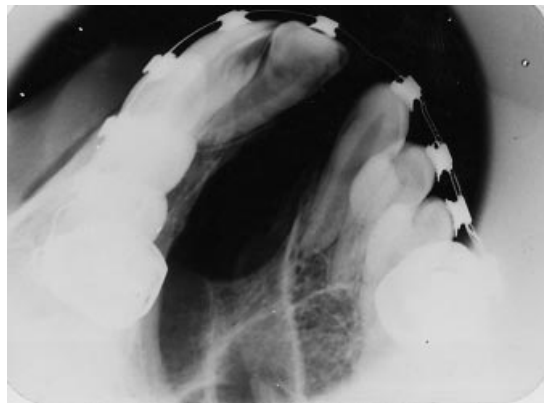


Figure 1 Anterior occlusal radiograph taken through the cleft site prior to bone-grafting. It highlights the absence of bone in the cleft site.

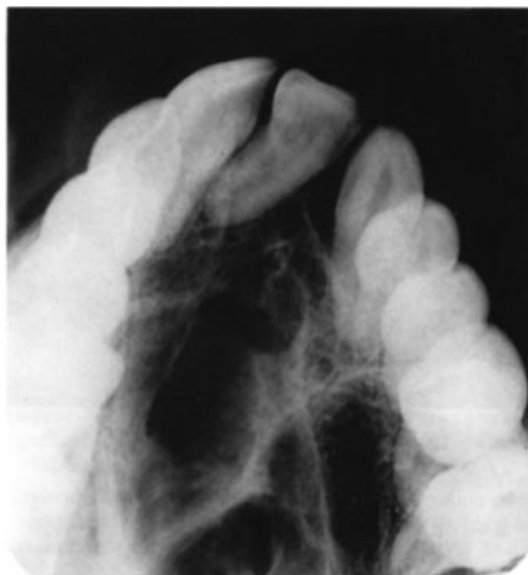

Figure 2 Anterior occlusal radiograph taken of the same patient post-bone-grafting. It shows a successful bone graft with the erupted cleft canine.

in this group. This is in agreement with the work of Bergland *et al.* (1986) who found less favourable results if grafting was performed after canine eruption.

The age at the time of surgery. The mean age of patients with Type I and Type II bone grafts was

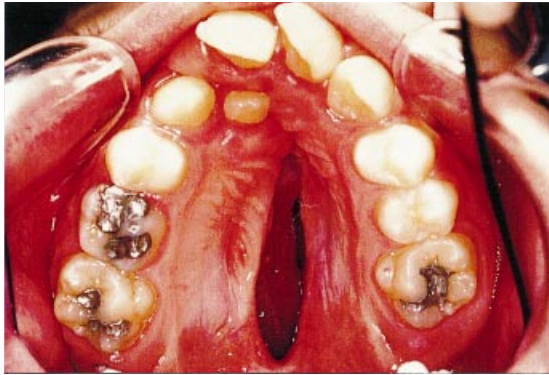


Figure 3 Occlusal photograph of the same patient illustrating the extent of the cleft.

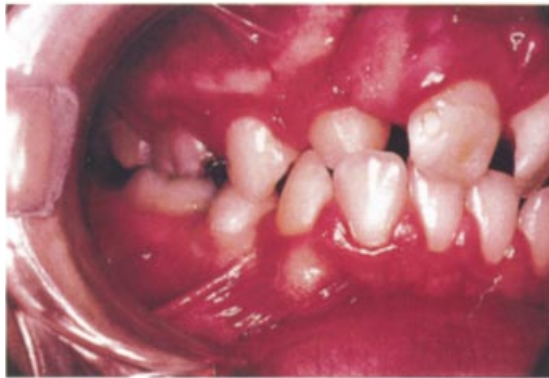

Figure 4 The cleft side prior to treatment.

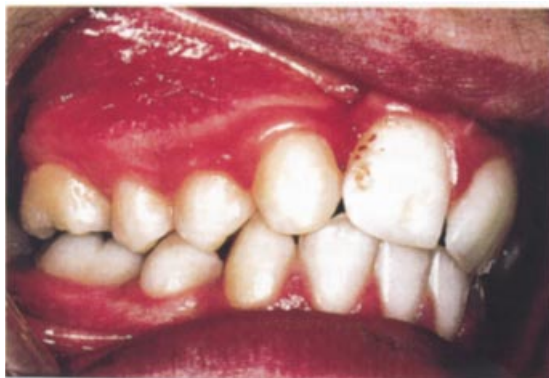

Figure 5 The occlusion on the cleft side after the completion of orthodontic treatment and bone-grafting.

10.5 years. However, the mean age for those with Type III and Type IV grafts was 11.7 and 12.8 years, respectively. Åbyholm *et al.* (1981) also found a higher failure rate when the osteoplasty was performed late. Waite (1987) explained that younger patients maintain their bone levels more than older patients, as the longer the untreated cleft exists, the more the alveolar bone levels proximal to the cleft resorb. Thus, the final graft height is determined by pre-existing alveolar bone levels.

Experience. Although Åbyholm *et al.* (1981) found the failure rate was higher in earlier operations, no such relationship was found in this study.

Infection. Whilst the oral hygiene status was not routinely recorded, nevertheless, 83 per cent of Types III and IV had reports of poor oral hygiene. This is something that needs to be carefully evaluated in the future.

Other reasons for failure. Amanat and Langdon (1991) have discussed other reasons for failure. These include the extraction of teeth at the time of alveoloplasty and excess surgery, together with scarring in the area of the proposed graft.

Timing

Although the mean age was 11.5 years, the age gradually reduced each year from 13.33 years in 1982 to 10.1 years in 1988. Bone grafting after 7–8 years is unlikely to interfere significantly with maxillary growth (Åbyholm *et al.*, 1981; Eldeeb, 1990). This is, therefore, the lower limit. There is no absolute upper limit and in this study one patient was successfully grafted at 18 years 9 months. However, the success rate is greatest in younger patients (Åbyholm *et al.*, 1981). The dental age also needs to be considered. Bone grafting should be performed before the eruption of the cleft canine (Boyne and Sands, 1972) when the root is half to two-thirds formed (Kortebein *et al.*, 1991). In this study however, timing was also dictated by the age at which the patient was referred.

Other complications

Cervical root resorption. The 3.6 per cent root resorption in this study compares favourably with other studies showing 3.3 per cent (Amanat and Langdon, 1991) and 5 per cent resorption (Bergland *et al.*, 1986). Cervical root resorption starts below the epithelial attachment and is progressive (Amanat and Langdon, 1991). Damage to the root cementum during surgery is a likely causal factor, as root cementum is highly specialized and lacks the ability to regenerate completely after surgery (Bergland *et al.*, 1986). Trauma to the periodontal ligament and drying of the root surface are similarly implicated (Amanat and Langdon, 1991). Osteoclastic activity of the cancellous marrow may also induce resorption, although this is reduced if cancellous bone from the jaw is placed against the root before iliac bone grafting (Amanat and Langdon, 1991).

Internal resorption. Two cases had internal resorption affecting the cleft canine which had erupted prior to bone grafting. Both occurred in males (a 14-year-old Asian and a 15-year-old Chinese) with unilateral clefts.

Retention of the cleft canine. Five canines were still unerupted at the time of the study. However, these patients were under 12 years of age and it is therefore likely that they will erupt.

Minor wound dehiscence. Although this study did not record dehiscence, it has been found in other studies, particularly in the presence of infection (Amanat and Langdon, 1991) and malpositioned central incisors (Hall and Posnick, 1983).

Proliferative granulation tissue. This occurred occasionally and was successfully treated by the topical application of silver nitrate.

Gait disturbance. Gait disturbance and lateral femoral cutaneous paraesthesia occurred occasionally, but was always transient.

Conclusions

This study assessed the success of 143 bone grafts. The interalveolar septal height was recorded

using the criteria of Bergland *et al.* (1986). A clinically successful result was achieved in 86.8 per cent. Less than three-quarters normal bone height was found in 10.9 per cent and 2.1 per cent of bone grafts failed. The latter two categories were found more commonly in bilateral clefts, where the canine had erupted prior to surgery, and in the older age group. The canine had erupted through the graft in 94 per cent of cases. The remaining patients were less than 12 years of age and hence the outcome of the cleft canine is not yet known. The main complications found in this study were internal resorption of the cleft canine (1.4 per cent) and cervical root resorption (3.6 per cent) of the adjacent incisor.

Address for correspondence

Dr M. Mars
Dental Department
The Hospital for Sick Children
Great Ormond Street
London WC1N 3JH
UK

References

- Åbyholm F, Bergland O, Semb G 1981 Secondary bone grafting of alveolar clefts. *Scandinavian Journal of Plastic and Reconstructive Surgery* 15: 127–140
- Amanat N, Langdon J P 1991 Secondary alveolar bone grafting in clefts of the lip and palate. *Journal of Cranio-Maxillofacial Surgery* 19: 7–14
- Bergland O, Semb G, Åbyholm F 1986 Elimination of the residual alveolar cleft by secondary bone grafting and subsequent orthodontic treatment. *Cleft Palate Journal* 23: 175–205
- Boyne P J, Sands N R 1972 Secondary bone grafting of residual alveolar and palatal clefts. *Journal of Oral Surgery* 30: 87–91
- Boyne P J, Sands N R 1976 Combined orthodontic/surgical management of residual palato-alveolar clefts defects. *American Journal of Orthodontics* 70: 20–37
- Carlton Schultz J 1989 Cleft palate fistula repair. *Journal of Cranio-Maxillofacial Surgery* 17: 34–36
- Eldeeb M 1990 Comment on a review paper on reconstruction of alveolar cleft with mandibular or iliac crest bone grafting. *Journal of Oral and Maxillofacial Surgery* 48: 559–560
- Eldeeb M E, Hinrichs J E, Waite D, Band C, Bevis M 1986 Repair of alveolar cleft defects with autogenous bone grafting: periodontal evaluation. *Cleft Palate Journal* 23: 126–136

- Enemark H, Simonsen E K, Schramm J E 1985 Secondary bone grafting in unilateral cleft lip and palate patients: indications and treatment procedures. *International Journal of Oral Surgery* 14: 2–10
- Enemark H, Sindet-Pedersen S, Bundgaard M 1987 Long-term results after secondary bone grafting of alveolar clefts. *Journal of Oral and Maxillofacial Surgery* 45: 913–918
- Eppley B, Scarlof A, Delfino J 1986 Secondary management of the pre-maxilla in bilateral cleft of the lip and palate patients. *Journal of Maxillofacial Surgery* 65: 987–988
- Hall D H, Posnick J C 1983 Early results in secondary bone grafts in 106 alveolar clefts. *Journal of Oral and Maxillofacial Surgery* 41: 289–294
- Hillerup S, Dahl E, Schwartz O, Hjorting-Hansen E 1987 Tooth transplantation to bone graft in cleft alveolus. *Cleft Palate Journal* 24: 137–141
- Jackson I T, Vandervord J G, McLennan J, Christie F B, McGregor J C 1982 Bone grafting of the secondary cleft lip and palate deformity. *British Journal of Plastic Surgery* 35: 343–353
- Kortebein M J, Nelson C, Sandove M 1991 Retrospective analysis of 135 secondary alveolar cleft grafts using iliac or calvarial bone. *Journal of Oral and Maxillofacial Surgery* 49: 493–498
- Lilja J, Moller M, Friede H, Lauritzen C, Petterson L E, Johanson B 1987 Bone grafting at the stage of mixed dentition in cleft lip and palate patients. *Scandinavian Journal of Reconstructive Surgery* 21: 73–79
- Maxson B, Baxter S, Vig K, Fonseca R 1990 Allogenic bone for secondary alveolar cleft osteoplasty. *Journal of Oral and Maxillofacial Surgery* 48: 933–941
- Rosenstein S, Dado D V, Kernahan D, Griffith B H, Grasseschi M 1991 The case for early bone grafting in cleft and palate: a second report. *Plastic and Reconstructive Surgery* 87: 644–653
- Sandove A M, Nelson C L, Eppley B L, Nguyen B 1990 An evaluation of calvarial and iliac donor sites in alveolar cleft grafting. *Cleft Palate Journal* 27: 225–228
- Sindet-Pedersen S, Enemark H 1988 Mandibular bone grafts for reconstruction of alveolar clefts. *Journal of Oral and Maxillofacial Surgery* 46: 533–537
- Verdi F, Lanzi G, Cohen S R, Powell R 1991 Use of the Bränemark implant in a cleft palate patient. *Cleft Palate and Craniofacial Journal* 28: 301–303
- Waite D 1987 Discussion on long-term results after secondary bone grafting in alveolar clefts. *Journal of Oral and Maxillofacial Surgery* 45: 919